

Review of left-to-right shunting patent ductus arteriosus and short term outcome in 98 dogs

The case records of 98 dogs with a left-to-right shunting patent ductus arteriosus (PDA) were reviewed. There were 35 breeds represented, with a female to male ratio of 3:1. Forty per cent of the dogs were older than one year at initial presentation and 31 per cent had clinical signs attributable to PDA. A left heart base continuous murmur of grade IV/VI or higher was noted in 90 per cent of the dogs. On electrocardiography, the most common abnormalities were tall R waves (63 per cent) and deep Q_{II} waves (62 per cent). The radiographic triad of dilation of the descending aorta with enlargement of the main pulmonary artery segment and left atrium, typical of PDA, was noted in only 26 per cent of cases. Two-dimensional (2D) and M-mode echocardiography detected left atrial enlargement (35 per cent) and an increased left ventricular diameter in diastole (82 per cent) and systole (84 per cent) as the most common abnormalities. Doppler echocardiography demonstrated increased aortic outflow velocities in 66 per cent of cases. The overall short-term successful outcome in this study was 95 per cent. There was no significant difference between surgical ductal ligation using a standard technique or the Jackson-Henderson technique in terms of survival, occurrence of haemorrhage or residual shunting. The number of interventional procedures used in this study was too low for statistical comparison, but there appeared to be a trend towards a higher rate of residual shunting and a lower fatality rate using a coil occlusion technique.

N. VAN ISRAËL, A. T. FRENCH,
J. DUKES-McEWAN AND
B. M. CORCORAN

Journal of Small Animal Practice (2002)
43, 395-400

Hospital for Small Animals, Royal
(Dick) School of Veterinary Studies,
Edinburgh University, Roslin
EH25 9RG

N. Van Israël's current address is:
Clinique Médicale des Petits
Animaux, Faculté de Médecine
Vétérinaire, Boulevard du Colorster
20 B44, B-4000 Liege, Belgium

Although several large epidemiological surveys of PDA in the dog have been published (Eyster and others 1976, Ackerman and others 1978, Buchanan 1994), as have studies evaluating the outcome in dogs following surgical ligation (Eyster and others 1975, Birchard and others 1990, Hunt and others 2001), few studies have documented the echocardiographic changes associated with PDA. The main objective of this study, therefore, was to evaluate 2D, M-mode and Doppler echocardiographic findings in a large number of cases and to compare clinical, electrocardiographic, and radiographic findings in this cohort group with previous studies. An additional aim was to compare complication rates, residual shunting and short term outcome between three different closure techniques: standard ductal dissection and double ligation (Buchanan 1994), dissection via the Jackson-Henderson technique (Jackson and Henderson 1979), and interventional closure using detachable coils (Stokhof and others 2000, Schneider and others 2001).

MATERIALS AND METHODS

The case records of 98 dogs diagnosed with a left-to-right shunting PDA at the Hospital for Small Animals of the Royal (Dick) School of Veterinary Studies between 1990 and 2000 were reviewed retrospectively. Diagnosis was based on demonstrating a PDA by colour flow Doppler echocardiography in all 98 cases, and was confirmed by thoracotomy and/or angiography in those cases where surgical ligation (n=73) or interventional closure (n=19) was attempted.

The history, signalment, clinical findings and laboratory data (haematology and serum biochemistry) were obtained from the case records. The electrocardiographic, radiographic and Doppler echocardiographic findings were reviewed by one author (N.V.I.). The six-lead electrocardiographic strips (ECGs) were assessed and measured according to the recommenda-

INTRODUCTION

The ductus arteriosus is a normal fetal structure that shunts blood from the pulmonary artery to the aorta. In the puppy, the ductus arteriosus functionally closes within days of birth (King 1999). Patent ductus arteriosus (PDA) is due to failure of this structure to close, and is one of the most commonly recognised congenital cardiac lesions in dogs (Patterson 1968, Tidholm 1997, Kitdeson 1998).

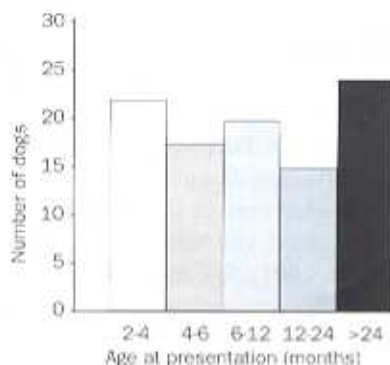


FIG 1. Age distribution at initial presentation

tions of Tilley (1992). The radiographs taken at initial presentation were mixed with equal numbers of thoracic radiographs of normal dogs and those with other cardiac abnormalities, and reviewed blind. Right lateral and dorsoventral thoracic radiographs were reviewed in couplets. Cardiomegaly was assessed using the vertebral heart scale (VHS, normal range 8.7 to 10.5) and the cardiothoracic ratio (intercostal space widths, normal range 2.5 to 3.5) methods (Buchanan 1972, Buchanan and Buchler 1995). Pulmonary perfusion was assessed in the dorsoventral view by comparing the width of the pulmonary artery and the width of the ninth rib where they crossed each other (Stickle and Anderson 1978) and, in the right lat-

eral view, by comparing the right cranial lung lobe vessels with the smallest portion of the fourth rib at the fourth intercostal space (Thrall and Losonsky 1976). Data from colour Doppler echocardiographic studies performed by multiple cardiologists were retrieved from the case records and compared with previously published normal values (Boon 1998). Animals with echocardiographic evidence of additional cardiac disorders were excluded from the analysis. The ultrasound studies were all performed on a Vingmed 700 (BMS, Scotland) or Esaote Challenge 3000 (Esaote, Italy) machine. M-mode measurements were obtained from the standard right parasternal short-axis view (Kittleson 1998). Left atrial size was assessed by a

combination of the 2D and M-mode findings. Maximal aortic outflow velocities were obtained via the subcostal view. Complication rates associated with ductal closure and short-term outcome (one month post-intervention) were also evaluated. Persistence of flow across the ductus was evaluated for those dogs that underwent an echocardiographic examination immediately post-occlusion.

Statistical analysis of the data was performed using Sigmapstat software (version 2.03, SPSS). Aortic velocities pre- and post-ligation were assessed using a paired *t* test. Residual shunting between groups was compared by the Fisher's exact test.

RESULTS

Full clinical records were available for 96 cases. ECGs were analysed for 76 of the dogs; laboratory data were available for 36 dogs; thoracic radiographs for 82 dogs; and echocardiographic data for 91 dogs (in seven cases precise M-mode and Doppler echocardiographic values were not available).

There were 35 breeds represented, the most common being German shepherd dogs (20 per cent), Cavalier King Charles spaniels (9 per cent), springer spaniels (8 per cent), crossbreeds (6 per cent) and border collies (5 per cent) (Table 1). There were 77 females and 21 males. The age range at the time of diagnosis was two to 120 months (mean 17.3 months, median seven months) (Fig 1). Forty per cent of

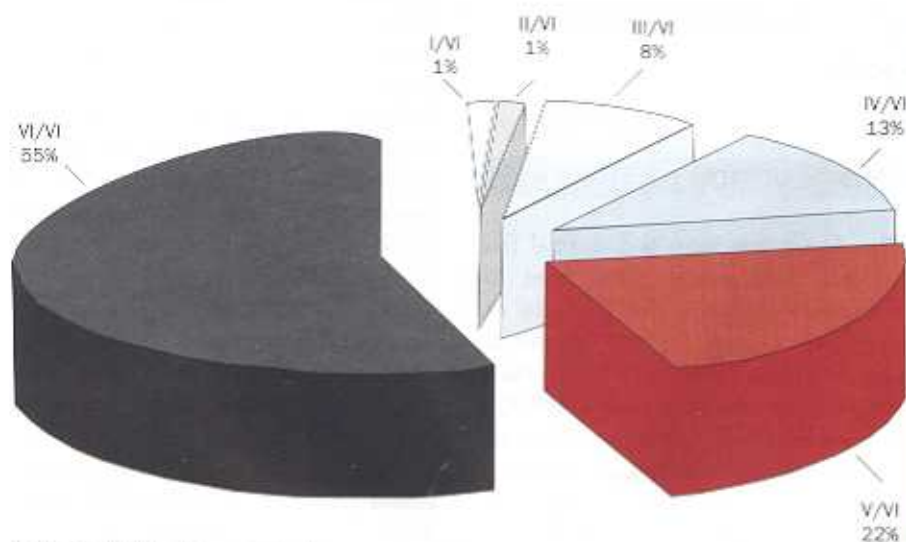


FIG 2. Distribution of murmur grades

Table 1. Breeds represented with PDA

n=	Breeds
20	German shepherd dog
9	Cavalier King Charles spaniel
8	Springer spaniel
6	Crossbreed
5	Border collie
4	Labrador, West Highland white terrier, Jack Russell terrier
3	Bichon frise, Brittany spaniel
2	Papillon, Shetland sheepdog, Yorkshire terrier, Welsh corgi, English cocker spaniel, Irish setter, terrier
1	Scottish deerhound, basset hound, weimaraner, Staffordshire bull terrier, flat coated retriever, bearded collie, borzoi, Tibetan spaniel, dachshund, Tibetan terrier, Newfoundland, German shorthaired pointer, border terrier, Dandie Dinmont terrier, Italian greyhound, chihuahua, Old English sheepdog

Table 2. M-mode echocardiographic findings compared with normal values for weight

M-mode	Normal* (%)	Increased (%)	Decreased (%)
IVSD	63	21	16
LVD	18	82	0
PWD	64	36	0
IVSS	57	15	28
LVS	16	84	0
PWS	67	25	8

*From Boon (1998)

IVSD/IVSS Interventricular septum in diastole/systole, LVD/LVS Left ventricular internal diameter in diastole/systole, PWD/PWS Left ventricular posterior wall in diastole/systole

Table 3. Ranges of fractional shortening (FS) as estimated from M-mode echocardiography

FS range	Percentage of animals
<20%	4
20-30%	25
31-40%	46
>40%	25
<35%	54

the dogs were one year or older at initial presentation. Bodyweight ranged from 1 to 39 kg (mean 12.5 kg, median 17.6 kg).

Clinical findings

Sixty-eight (69 per cent) dogs showed no clinical signs; a murmur was detected at vaccination in 49 per cent of these cases. Of the clinically affected dogs, 13 were coughing, 12 were dyspnoeic, 12 were exercise intolerant and 26 had retarded growth. Furthermore, 10 dogs had abnormal mucous membrane colour (five pale, five congested) and 6 per cent had jugular distension. Those animals that had clinical signs were significantly older ($P<0.05$) (median age 24 months versus seven months for dogs showing no clinical signs), but no breed difference could be detected.

A precordial thrill was palpable in 80 per cent of all cases and in 90 per cent of the animals a left basal continuous murmur with a grade equal to or higher than IV/VI (Fig 2) was auscultated. Additional systolic murmurs were audible in 29 per cent of the cases (the majority [89 per cent] were presumed to be mitral in origin). The

heart rate was normal in 95 per cent of the dogs, and 32 per cent appeared to be in sinus arrhythmia. No bradycardias were auscultated. Atrial fibrillation was noted in four adult dogs (age range 12 to 96 months). The pulse was found to be bounding in 75 per cent of cases. Ascites, consistent with right-sided heart failure, was noted in only two dogs.

Electrocardiographic findings

On electrocardiography, the most common abnormality was tall R waves and this was present in 63 per cent of cases (range 1.1 to 11.5 mV; normal <2.5 mV in small breeds, <3 mV in large breeds). Deep Q waves (range 0 to 2.6 mV; normal <0.5 mV) were seen in lead II in 62 per cent of cases. A combination of the two was seen in 43 per cent of cases. Tall P waves (>0.4 mV) were seen in 12 per cent and wide P waves (>0.04 second) in 18 per cent of the dogs; a combination of the two occurred in only 5 per cent of the dogs. The majority of the dogs were in sinus rhythm (67 per cent) or had a sinus arrhythmia (18 per cent). Atrial or ventricular premature complexes were noted in 12 per cent of cases and atrial fibrillation in only 3 per cent. Ventricular tachycardia was not observed. There was right-axis deviation in 11 per cent of cases and left-axis deviation in 3 per cent.

Laboratory data

Analysis of the available laboratory data revealed marginally low packed cell volume in 5 per cent of cases (minimum 24.3

litres/litre; reference range 39.0 to 55.0 litres/litre), azotaemia in 22 per cent (43 per cent of which were receiving diuretics) and low total protein in 45 per cent of dogs older than six months (range 47.9 to 56.0 g/litre; reference range 58.0 to 73.0 g/litre).

Radiographic findings

Cardiomegaly was evident in 80 per cent of the dogs on thoracic radiography when using the VHS system (mean VHS 11.5, median 11.75; range 8.5 to 15.5) but in only 36 per cent when the cardiothoracic ratio method was used. The right ventricle (91 per cent) and left ventricle (62 per cent) were the chambers interpreted as being most commonly enlarged. The left atrium appeared enlarged in 51 per cent of the radiographs and tracheal elevation was noted in 48 per cent of the cases. The right atrium appeared enlarged in only 21 per cent of the radiographs. The typical three bulges (aortic, pulmonary and auricular) on dorsoventral radiographs were only visible in 26 per cent of cases, while an aortic bulge, pulmonary artery bulge or auricular bulge was seen in isolation in 77 per cent, 72 per cent and 34 per cent of the cases, respectively. The typical PDA heart (Suter and Lord 1977) was observed in 52 per cent of the radiographs analysed. Increased sternal contact was detected in 57 per cent of cases. Overperfusion of the pulmonary vasculature was more evident on the dorsoventral view (76 per cent) than on the right lateral view (24 per cent). Pulmonary oedema was evident in 18 per cent of cases. The distribution of the oedema was mainly hilar (80 per cent), although general (14 per cent) and focal (6 per cent right caudal lung lobe) oedema was sometimes noted.

Colour Doppler echocardiography findings

Colour Doppler echocardiography revealed the presence of concurrent defects in 10 of 98 cases (six dogs had aortic stenosis, and there were individual cases of pulmonary stenosis, mitral dysplasia, mitral

Table 4. Maximal velocities across the aortic valve measured by continuous wave Doppler echocardiography from the subcostal view before and after ductal closure

Dog number	Ao velocity pre-closure (m/second)	Ao velocity post-closure (m/second)	Difference (m/second)	Percentage*
25	2.0	0.8	1.2	60
40	1.5	1.2	0.3	20
42	2.0	2.0	0.0	0
44	1.1	1.1	0.0	0
48	1.7	0.8	0.9	53
53	2.4	1.5	0.9	38
54	2.7	1.1	1.6	59
56	1.7	0.9	0.8	47
59	2.0	0.9	1.1	55
62	1.7	1.6	0.1	6*
65	2.2	1.5	0.7	32
71	1.3	1.0	0.3	23
73	2.1	0.9	1.2	57
78	1.9	1.5	0.4	21
86	2.8	1.3	1.5	54
92	2.1	1.0	1.1	52
94	1.7	1.4	0.3	18
101	3.7	1.5	2.2	59

*A greater than 20 per cent difference is likely to reflect true change that is independent of operator, observer and day-to-day variation (Dukea-McEwan and others 2001)
 †Still residual flow

endocardiosis, double chambered left ventricle, and persistent left cranial vena cava and azygos). With the exception of the last case, all these were excluded from the analysis of the echocardiographic data. The changes in myocardial wall thickness and left ventricular diameters, as seen on M-mode echocardiography, are listed in Table 2. Fractional shortening values (range 15 to 49 per cent) are shown in Table 3. E-point septal separation was more than 5 mm in 44 per cent of cases and more than 8 mm in 17 per cent of cases. The left atrium appeared enlarged in one-third of the cases and was severe in 10 per cent. Velocities across the aortic valve were greater than 1.5 m/second in 66 per cent of cases (range 1.0 to 3.7 m/second, mean 2.16 m/second). Velocities across the pulmonary artery were greater than 1.2 m/second in 17 per cent of cases (range 0.6 to 2.2 m/second). Concurrent mitral regurgitation was present in 40 per cent of the animals. The ductus was clearly visualised in 71 of the 91 cases. More than 20 per cent variation in aortic outflow velocity occurred in 14 out of 18 cases after ligation or embolisation of the PDA (mean velocity post-ligation 1.32 m/second) (Table 4).

Treatment and outcome

Treatment by means of surgical ligation (73 dogs in total; 49 standard technique, 24 Jackson-Henderson technique) and/or an interventional procedure (19 dogs in total; Rashkind occluder in three, Cook detachable coil(s) in 16), was performed randomly in 90 per cent of the cases. Six per cent received medical treatment only, as recommended by the clinician in charge, and 4 per cent did not receive any treatment. The ductus diameter, as measured at thoracotomy or estimated by angiography, ranged from 2 to 20 mm at the pulmonary artery side (Table 5).

Complications occurred in 32 per cent of the dogs undergoing surgical ligation and in 52 per cent of the dogs undergoing interventional procedures. The surgical complications included haemorrhage (total 11 per cent; Jackson-Henderson technique 8.3 per cent, standard technique 12.2 per cent), cardiac arrest (6 per cent), wound seroma (4 per cent), atrial fibrillation (4 per cent), pneumothorax (3 per cent), pronounced Brnham's reflex (3 per cent) (King 1999), chylothorax (1 per cent), pulmonic stenosis post-surgery (1 per cent), laryngeal paralysis (1 per cent),

Table 5. Ductal size as estimated at thoracotomy or on angiography (n=31)

Size	Number (%) of animals
<3 mm	2 (6)
3.5-9 mm	1 (3)
6.9-9 mm	16 (52)
10-14.9 mm	9 (29)
>14.9 mm	3 (10)

iatrogenic lung wound (1 per cent), acute heart failure (1 per cent) and transient ventricular arrhythmias (1 per cent). The interventional complications consisted of femoral artery haemorrhage (16 per cent), aortic embolisation (11 per cent), pulmonary artery embolisation (5 per cent), haemolysis (5 per cent) and technical problems.

The total short term (one month post-closure) survival rate was 95 per cent. There was a 3 per cent surgical death rate due to haemorrhage (Jackson-Henderson technique equal to standard dissection), a 1 per cent interventional death rate due to fatal femoral artery haemorrhage (Rashkind occluder), and a 1 per cent anaesthetic death rate (cardiac arrest in the preoperative period). Persistence of a continuous murmur three days post-intervention was recorded in 22 per cent of the cases where post-ligation data were available (6/37 standard technique, 3/14 Jackson-Henderson technique and 5/9 coil occlusion). Persistence of flow across the ductus was identifiable on colour flow echocardiography in 43 per cent of cases scanned before discharge (18/37 standard technique, 5/14 Jackson-Henderson technique, 5/9 coil occlusion).

DISCUSSION

The breed distribution in this study differed slightly from previous reports (Eyster and others 1976, Buchanan 1994). Of particular interest was the apparently high prevalence of Cavalier King Charles spaniels in this group, although it was not possible to calculate the true incidence in the authors' referral population. Although

a hereditary aspect to PDA (a polygenic threshold trait) is recognised (Patterson and others 1971), the presence of cross-breed dogs in this study is similar to that reported by Kittleson (1998). The gender ratio was the same as that previously reported by Eyster and others (1976).

The high number of adult dogs presented in this series contrasts with the studies of Ackerman and others (1978) and Goodwin and Lombard (1992) who reported 32 and 25.5 per cent, respectively, and indicates that a significant number of PDA-affected dogs are not being identified at first vaccination. The age at presentation might also be biased due to the fact that the study involved a referral population. While it is commonly stated that most PDA-affected dogs will go into left-sided heart failure at a young age (Patterson and others 1971, Kittleson 1998), a high number of adult dogs without overt signs of left-sided congestive heart failure was seen in this study. A possible explanation is that dogs with congestive heart failure may have died prior to referral or may not have been referred at all.

The hallmark of PDA is a continuous murmur over the left heart base (Smetzer and Breznock 1972), which was present in every single dog in this study. As previously stated, most murmurs are loud (Smetzer and Breznock 1972) and, in this study, 90 per cent of the murmurs were grade IV or above. Mitral valve incompetence, attributable to mitral valve dilation and stretch (Goodwin and Lombard 1992, Pouchelon and others 1997) and papillary muscle displacement (Kittleson 1998) secondary to left ventricular volume overload, is a frequent finding in association with PDA (Weirich and others 1978). This explains the presence of a concurrent systolic murmur in 25 per cent of the cases. A bounding pulse is another commonly recognised diagnostic feature of PDA and was detected in 75 per cent of the cases in this study.

The electrocardiographic findings in this study were indicative of left ventricular enlargement and concur with previous

studies (Ackerman and others 1978). However, the high incidence of deep Q waves in lead II, suggestive of right ventricular enlargement (Tilley 1992), contrasts with the report by Ackerman and others (1978). The concurrent right ventricular enlargement may be related to volume overload and to subclinical pulmonary hypertension secondary to chronic volume overload (Lord 1974). The high incidence of sinus arrhythmia and the low incidence of atrial fibrillation is in accordance with the low incidence of congestive heart failure in this study population. Atrial fibrillation, known to be a late clinical finding and normally associated with a grave prognosis (Weirich and others 1978), was only seen in adult dogs.

Azotaemia was detected in the study population and, while it is a common finding in low-output heart failure, in some cases the use of diuretics is a more likely explanation (Bush 1997). The low total protein levels identified in nearly half the animals over six months of age, may be explained in some cases by haemodilution due to volume overload and chronic congestive heart failure (Ertinger 2000). Stunted growth was noted in many dogs in this study. Release of cytokines (eg, tumour necrosis factor- α , interleukin 1 and 6) has been associated with cardiac cachexia (Freeman and others 1995) and it is possible that these factors, together with a reduced growth metabolism (Bush 1997), result in poor growth in animals with congenital heart disease, as noted by Tidholm (1997).

Radiographic signs of left atrial, left ventricular, main pulmonary artery and aortic arch enlargement are well recognised features in canine PDA (Buchanan 1972), and were readily identifiable in this study. However, the radiographic triad pathognomonic of PDA (dilation of the descending aorta, with enlargement of the main pulmonary artery segment and left atrium) (Stickle and Anderson 1978) was only present in 25 per cent of cases. The apparent right ventricular enlargement in a large number of cases might be attributed, as

stated previously, to volume overload and to subclinical pulmonary hypertension secondary to chronic volume overload (Lord 1974). Alternatively, it has been previously reported that left ventricular enlargement can produce a radiographic image which mimics right ventricular enlargement (Ackerman and others 1978). Unfortunately, no echocardiographic data regarding the presence or absence of right ventricular enlargement were available on which to base definite conclusions. An interesting outcome of this study was that the generalised cardiomegaly determined by the VHS method correlated much better with the echocardiographic findings than when assessed using the cardiothoracic ratio. Pulmonary perfusion was best assessed radiographically using the dorsoventral view rather than the right lateral view. This contrasts with a previous report by Thrall and Losonsky (1976).

The M-mode echocardiographic findings in this study contrast with the report of Wingfield and Boon (1987) in that not all dogs had the typical association with volume overload, such as increased left ventricular diameter in diastole and systole, and decreased left ventricular posterior wall thickness, and interventricular wall thickness in diastole and systole. Left ventricular wall thickness was often within normal limits. There was a wide variation in fractional shortening percentage, as previously reported by Goodwin and Lombard (1992). In dogs with a left-to-right shunting PDA and left ventricular volume overload, left ventricular hyperkinesis would be the expected compensatory response of the non-failing myocardium (Frank-Starling mechanism). The presence of mitral regurgitation, as seen in 40 per cent of the dogs in this study, would further enhance the fractional shortening. Hypokinesis is usually interpreted as representing the onset of myocardial failure. Using a cut-off value for fractional shortening of 30 per cent, nearly one-third of the dogs in the present study exhibited evidence of hypokinesis and possible myocardial failure. However, this might be a

conservative figure and, unfortunately, other indices of systolic function, such as ejection fraction and systolic time intervals, were not available to enable left ventricular function to be assessed. Left atrial enlargement was identified echocardiographically, as has been previously reported (Corti and others 2000).

The increased velocities across the aortic valve in PDA have previously been attributed to volume overload (Boon 1998) and the significant reduction of the outflow velocity after ductal closure seen here supports this finding (paired *t* test, $P < 0.001$). A margin of more than 20 per cent difference was taken because values above this are likely to reflect true change that is independent of operator, observer and day-to-day variation (Dukes-McEwan and others 2002).

The overall surgical outcome and rate of complications observed in this study were very similar to those previously reported (Eyster and others 1975, Jackson and Henderson 1979, Birchard and others 1990, Bellenger and others 1996, Hunt and others 2001). However, there was no significant difference between the two surgical techniques in terms of survival, occurrence of haemorrhage or residual shunting, in contrast to anecdotal reports by Buchanan (1994) and Jackson and Henderson (1979). Although the number of interventional procedures used in this study was too low to allow statistical analysis, there did appear to be a trend towards a higher rate of residual shunting and a lower fatality rate using the coil occlusion technique. The residual shunting rate seen at the time of discharge by colour Doppler echocardiography was much higher than that previously reported (Miller and others 1994, Schneider and others 2001). In the surgical cases, this may be related to surgical experience and type of suture material used, while in the interventional procedures it was most likely to be due to an inadequate number and/or size of coils. However, late closure has been reported with the use of coils (Stokhof and others 2000).

The clinical significance of residual shunting and myocardial failure remains unknown and long term follow-up studies are necessary to determine this.

Acknowledgements

The authors would like to thank the veterinarians responsible for referring these cases, all the clinicians involved in the case management and, in particular, colleagues within the surgery department for their help with the surgical treatment of these dogs.

References

- ACKERMAN, N., BURR, R., HUNT, A. W. & HAYES, H. M. (1978) Patent ductus arteriosus in the dog: a retrospective study of radiographic, epidemiologic, and clinical findings. *American Journal of Veterinary Research* **39**, 1805-1810
- BELLENGER, C. R., HUNT, G. B., GOLDSMID, S. E. & PEARSON, M. R. B. (1996) Outcome of thoracic surgeries in dogs and cats. *Australian Veterinary Journal* **74**, 23-30
- BIRCHARD, S. J., BOWLING, J. D. & ENGLAND, R. B. (1990) Results of ligation of patent ductus arteriosus: 201 cases (1969-1988). *Journal of the American Veterinary Medical Association* **196**, 2011-2013
- BOON, J. A. (1998) *Manual of Veterinary Echocardiography*. Williams & Wilkins, Baltimore, pp 186-209, 363-445, 453-473
- BUCHANAN, J. W. (1972) Radiographic aspects of patent ductus arteriosus in dogs before and after surgery. *Acta Radiologica Supplementa (Stockh)* (Supplement) **319**: 271-278
- BUCHANAN, J. W. (1994) Patent ductus arteriosus. *Seminars in Veterinary Medicine and Surgery (Small Animal)* **9**, 68-176
- BUCHANAN, J. W. & BUCKNER, J. B. (1995) Vertebral scale system to measure heart size in radiographs. *Journal of the American Veterinary Medical Association* **206**, 194-199
- BUSH, B. M. (1997) Total protein. Causes of increased plasma urea levels. In: *Interpretation of Laboratory Results for Small Animal Clinicians*. Blackwell Science, London, pp 227-247
- CORTI, L. B., MERKLEY, D., NELSON, O. L. & WARE, W. A. (2000) Retrospective evaluation of occlusion of PDA with hemoclips in 20 dogs. *Journal of the American Animal Hospital Association* **36**, 548-555
- DUKES-MCEWAN, J., FRENCH, A. T. & CORCORAN, B. M. (2002) Doppler echocardiography in the dog: measurement variability and reproducibility. *Veterinary Radiology and Ultrasound* **43**, 144-152
- ETTINGER, S. J. (2000) Dietary modifications in cardiac disease. In: *Textbook of Veterinary Internal Medicine*, 5th edn. Eds S. J. Ettinger and E. C. Feldman. W. B. Saunders, Philadelphia, p 263
- EYSTER, G. E., EYSTER, J. T., CORDES, B. C. & JOHNSTON, J. (1976) Patent ductus arteriosus in the dog: Characteristics of occurrence and results of surgery in one hundred consecutive cases. *Journal of the American Veterinary Medical Association* **168**, 435-438
- EYSTER, G. E., WHIPPLE, R. D., EVANS, A. T., HOUGH, J. D. & ANDERSON, L. K. (1975) Recanalized patent ductus arteriosus in the dog. *Journal of Small Animal Practice* **16**, 743-749
- FREEMAN, L. M., RUSH, J. E., BROWN, D. J. & KEHAVIAS, J. J. (1995) The use of fish oil in dogs with congestive heart failure. (ACVIM abstract). *Journal of Veterinary Internal Medicine* **9**, 199-203
- GOSWAMI, J. K. & LOMBARO, C. W. (1992) Patent ductus arteriosus in adult dogs: clinical features of 14 cases. *Journal of the American Veterinary Medical Association* **28**, 349-354
- HUNT, G. B., SWANSON, D. J., BECK, J. A., GOLDSMID, S. E., LAWRENCE, D., PEARSON, M. R. B. & BELLENGER, C. R. (2001) Intra-operative haemorrhage during PDA ligation in dogs. *Veterinary Surgery* **30**, 58-63
- JACKSON, W. F. & HENDERSON, R. A. (1979) Ligature placement in closure of patent ductus arteriosus. *Journal of the American Animal Hospital Association* **15**, 55-58
- KING, A. S. (1999) Foetal and neonatal circulation and respiration. In: *The Cardiorespiratory System*. Blackwell Science, London, pp 391-414
- KITTLESON, M. D. & KIEHL, R. D. (1998) Patent ductus arteriosus. In: *Small Animal Cardiovascular Medicine*. Eds Kittleson and Kiehl. Mosby, St Louis, pp 218-230
- LORD, P. F. (1974) Left ventricular volumes of diseased canine heart: congestive cardiomyopathy, and volume overload (PDA and primary mitral valvular insufficiency). *American Journal of Veterinary Research* **35**, 493-501
- MILLER, M. W., STONE, R. L., MEURS, K. M. & BOSWOOD, A. (1994) Echocardiographic assessment of PDA after occlusion. Proceedings of the 14th ACVIM forum, Orlando, p 305
- PATERSON, D. F. (1968) Epidemiologic and genetic studies of congenital heart disease in the dog. *Circulation Research* **XXIII**, 171-202
- PATERSON, D. F., PYLE, R. L., BUCHANAN, J. W., TRAUTVETER, E. & APT, D. A. (1971) Hereditary patent ductus arteriosus and its sequelae in the dog. *Circulation Research* **XXIX**, pp 1-13
- POUGHEON, J. L., CHATELAIN, V., GARNIER, E., BRISCHER, L. & GALLIX, P. (1997) Proposition d'une classification échocardiographique de la persistance du canal artériel chez le chien à partir de 24 cas. *Revue de Médecine Vétérinaire* **172**, 623-642
- SCHNEIDER, M., HEIDBRANDT, N., SCHWEIG, T. (2001) Transvenous embolization of small patent ductus arteriosus with single detachable coils in dogs. *Journal of Veterinary Internal Medicine* **18**, 222-228
- SMEETZER, D. C. & BRZESOCK, E. M. (1972) Auscultatory diagnosis of PDA in the dog. *Journal of the American Veterinary Medical Association* **160**, 90-94
- SNICKLE, R. L. & ANDERSON, L. K. (1978) Diagnosis of common congenital heart anomalies in the dog using survey and non-selective contrast radiography. *Veterinary Radiology* **28**, 6-12
- STOKHOF, A. A., SREERAM, N. & WOLVERAMP, W. T. C. (2000) Transcatheter closure of patent ductus arteriosus using occluding spring coils. *Journal of Veterinary Internal Medicine* **14**, 452-455
- SUTER, P. F. & LORD, P. F. (1977) Patent ductus arteriosus. In: *Thoracic Radiography*. Wettswill, pp 497-502
- THRALL, D. E. & LOSCOKSKY, J. M. (1976) A method for evaluating canine pulmonary circulatory dynamics from survey radiographs. *Journal of the American Animal Hospital Association* **12**, 457-462
- TIDHCLM, A. (1997) Retrospective study of congenital heart defects in 151 dogs. *Journal of Small Animal Practice* **38**, 94-98
- TILLEY, L. P. (1992) Analysis of canine P-QRS-T deflections. In: *Essentials of Canine and Feline Electrocardiography*, 3rd edn. Lea & Febiger, Philadelphia, pp 58
- WEIRICH, W. E., BLEVINS, W. E. & REAR, A. H. (1978) Late consequences of PDA in the dog: a report of 6 cases. *Journal of the American Animal Hospital Association* **14**, 40-51
- WINGFIELD, W. E. & BOON, J. A. (1987) Echocardiography for the diagnosis of congenital heart defects in the dog. *Veterinary Clinics of North America: Small Animal Practice* **7**, 735-753