

# Retrieval of a patent ductus arteriosus coil following embolisation to the right subclavian artery

**A two-month-old female Tibetan terrier was re-presented with an incomplete closure of the patent ductus arteriosus. Following a second attempt to close the shunt by coil embolisation, arterial embolisation occurred. The successful removal of the embolised coil is described.**

N. VAN ISRAËL AND A. T. FRENCH

*Journal of Small Animal Practice* (2002)  
43, 136–138

## INTRODUCTION

Coil embolisation is now a widely accepted alternative method for the closure of patent ductus arteriosus (PDA) in the dog. Arterial embolisation is an uncommon but potentially dangerous complication of the technique. The following report describes the closure of a residual PDA shunt by coil embolisation and the successful percutaneous retrieval of an embolised coil with the aid of a retrieval snare.

## CASE HISTORY

A two-month-old female Tibetan terrier was presented for the closure of a patent ductus arteriosus (PDA). Clinical examination, electrocardiography and thoracic radiography were consistent with a left-to-right shunting PDA. The diagnosis was confirmed by two-dimensional and M-mode echocardiography, demonstrating volume overload of the left atrium and ventricle, and colour flow Doppler echocardiography, detecting the presence of continuous retrograde flow in the pulmonary artery.

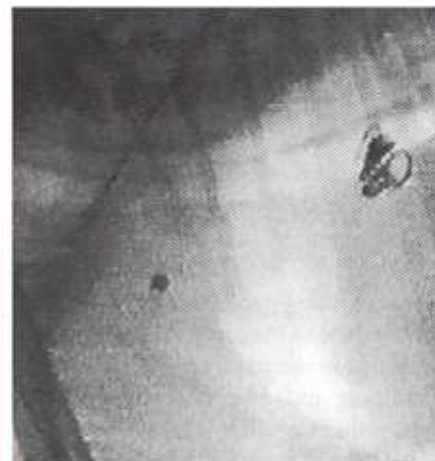Under general anaesthesia and under fluoroscopic guidance, the PDA was catheterised by a retrograde left femoral arterial approach and two embolisation coils (MWCE-6-PDA 5, MWCE-5-PDA 5) (MR eye detachable coil; Cook) were positioned in the ampulla. Unfortunately, the closure was incomplete and a residual shunt persisted.

On re-presentation, four months later, the dog was very bright and alert. It was fully grown and completely free from clinical signs of disease. Clinical examination

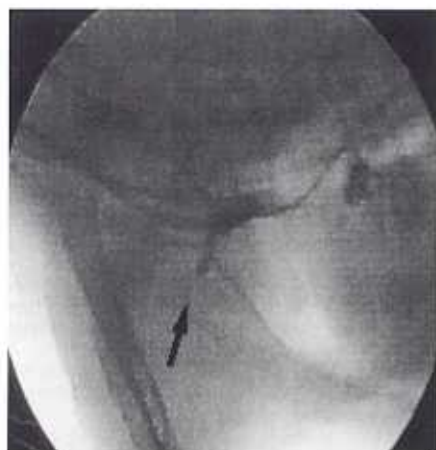
was, beside a grade 3/6 continuous murmur over the left heart base, unremarkable. Colour Doppler echocardiography confirmed the persistence of flow across the PDA. The left ventricle and left atrium were still mildly enlarged, suggestive of volume overload. A low grade mitral regurgitation was present.

Under general anaesthesia and fluoroscopic guidance, and via the transarterial right femoral approach, two more coils (MWCE-3-PDA 5) (MR eye detachable coil; Cook, Bjaeverskov) were placed on top of the previously placed coils, because an attempt to anchor a loop of the new coils to the previously placed coils was unsuccessful. Unfortunately, the second coil embolised cranially into the systemic circulation (Fig 1). Selective angiography (iothalamate, Conray 420; Mallinckrodt, Bicester) revealed that the coil was lodged in the right subclavian artery causing complete occlusion (Figs 2 and 3).

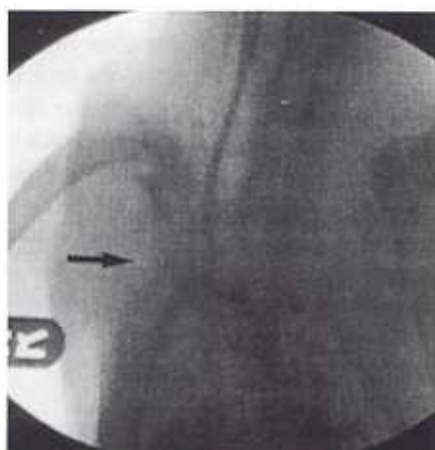
A nitinol gooseneck snare (Microvena Corporation) was introduced via the already positioned 5 French gauge introducer sheath (Check Flo performer; Cook). The snare was advanced to the coil, which was successfully grasped and withdrawn as a unit through the introducer sheath (Fig 4). The dog was stable during and after the procedure and was discharged three days later.



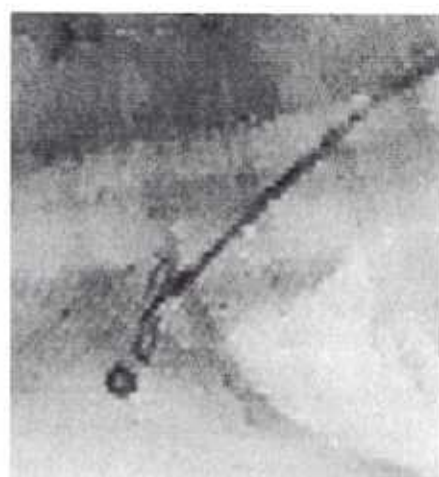
**FIG 1.** Fluoroscopic image of the cranial thorax (right lateral view), showing the three properly positioned coils in the ductus and the embolised coil



**FIG 2.** Fluoroscopic image of a direct angiogram (right lateral view) showing complete occlusion of the right subclavian artery by the embolised coil (arrow)



**FIG 3.** Fluoroscopic image of a direct angiogram (ventrodorsal view), showing complete occlusion of the right subclavian artery by the embolised coil (arrow)



**FIG 4.** Fluoroscopic image of the lateral cranial thorax, showing the Microvena nitinol retrieval snare approaching the embolised coil

An insignificant amount of residual shunting, consistent with a grade 1 continuous murmur on auscultation, remained on colour Doppler echocardiography three days post-intervention, but complete closure was present at a recheck examination five months later.

## DISCUSSION

Coil embolisation is now a widely accepted alternative method for the closure of a PDA in the dog (Glaus and others 1999, Miller 2000, Stokhof and others 2000).

Possible complications of coil embolisation include excessive protrusion of the coils in the pulmonary artery or aorta (Miller 2000), pulmonary artery or aortic embolisation (Snaps and others 1995, Glaus and others 1999, Miller 2000), residual shunting, haemolysis (Van Israël and others 2001) and haemorrhage at the introducer site (Glaus and others 1999). Pulmonary artery embolisation does not seem to cause any problems (Saunders and others 1999, Miller 2000, Stokhof and others 2000).

Although mechanical dislodgement (by delivery catheter or guide wire) is a common reason for movement of a coil, thorough analysis of the video of the procedure in the present case could not identify any user intervention to explain the cause of

dislodgement. The coil probably dislodged because it was not anchored to one of the previously placed coils and because it was not positioned deep enough in the ampulla. The failure of anchoring of the coil was attributed to the presence of thrombus formation and the known endothelialisation of coils (Tomita and others 2000).

It is unclear why the coil flew upstream, but abnormal turbulent flow (vortex-like) in that area is a possible explanation as to why the coil was guided in the direction of the right subclavian artery. The turbulence could have been created by the presence of a dilated aortic ampulla, the ductus ampulla and the concurrent partial obstruction of the descending aorta by the Jackson delivery catheter (5 French gauge). The dog was positioned in right lateral recumbency and gravity might also have played a role.

In the present case, despite the current evidence that dogs develop excellent collateral circulation (Christie 1980, Butkovic and others 1996, Buchanan and others 1997, Whigham and others 1998), a decision was made to retrieve the coil because rare, but potentially serious, complications have been associated with retained vascular foreign bodies (thromboembolisation, sepsis, aneurysms and vascular perforation) (Fisher and Ferreyro 1978).

In human medicine, misplaced coils have been retrieved percutaneously from various sites (the aorta [Weber 1980, Chuang and others 1981, Vujic and others 1986], external iliac artery [Chuang and others 1981], ileocolic artery [Vujic and others 1986], internal carotid artery [Cekirge and others 1995] and the pulmonary artery [Yedlicka and others 1991]) since Thomas and others (1964) retrieved a vascular foreign body for the first time in 1964.

Different retrieval devices have been used for recovering foreign bodies in human medicine: for example, Dormier baskets (Chuang 1979, Chuang and others 1981), grasping forceps (Thomas and others 1964, Vujic and others 1986) and loop snares (Yedlicka and others 1991, Edwards and others 1993, Tajima and others 1994, Cekirge and others 1995).

There are few reports of percutaneous foreign body retrieval in the veterinary literature. An experimental study was performed by Yedlicka and others (1991) which assessed the nitinol gooseneck snare for removal of wire and catheter fragments introduced into the thoracic vasculature of four dogs. Two other publications (Fox and others 1985, Hoskinson and others 1991) describe the non-surgical removal of a catheter embolus from the right heart of a dog and a horse. Several devices (horse

hair brush, alligator forceps and a basket) (Takehashi and others 1988, Rawlings and others 1994, Borgarelli and others 1997) have been used to retrieve heartworms via the right jugular vein from both dogs and cats. To the authors' knowledge, successful retrieval of a misplaced coil in the systemic arterial circulation of a dog has not been reported previously.

Grasping forceps and baskets have been found to be more effective than loop snares if the foreign body migrates distally and lodges in a small vessel, since it is impossible to advance the standard size snare loops distal to the foreign body (Vujic and others 1986). Despite being lodged distally in a small artery, the ensnarement of the coils was not a major problem in the present case. Although the coils are radiopaque, control of the snaring manoeuvre was nevertheless impaired because of the two-dimensional limitation of fluoroscopic imaging. Therefore, the two different views (ventrodorsal and lateral) obtained with selective angiography were very useful for more appropriate localisation of the embolised coil.

A nitinol gooseneck snare was selected because this was the only retrieval system that could fit the 5 French gauge introducer sheath. The snare is constructed of a nickel titanium cable, and it is not necessary to heat or cool the snare for introduction. The snare loop is at a right angle to the cable and its radiographic visualisation is enhanced by gold-plated tungsten coils, which are an integral part of the cable. The cable shaft is covered by thin-walled, Teflon shrink-wrapped tubing to reduce friction (Yedlicka and others 1991).

Although the present case report states that closure of a residual shunt is feasible, it appears technically more difficult than initial closure and to carry a higher risk of

embolisation; therefore, complete closure of the PDA should always be the goal at the initial intervention. If a secondary closure is necessary, it is preferable that additionally placed coils are anchored to previously placed coils, to avoid embolisation. Mapping out the shelf of the duct and margin of the aorta at fluoroscopy, to ensure that the coils are within the ampulla of the duct, is strongly recommended.

### Conclusions

With wider adoption of coil embolisation in the treatment of PDA in dogs, veterinarians should be aware of the possibility of closure of a residual shunt by coil embolisation and that retrieval of a misplaced coil in the systemic arterial circulation is feasible.

### References

BORGARELLI, M., VENCO, L. & PIGA, P. M. (1997) Surgical removal of heartworms from the right atrium of a cat. *Journal of the American Veterinary Medical Association* **211**, 68-69

BUDOWSKI, J. W., BEARDON, A. W. & SARKIS, C. (1997) Femoral artery occlusion in Cavalier King Charles spaniels. *Journal of the American Veterinary Medical Association* **211**, 872-875

BUTKOVIĆ, V., ČOVAL, D. & STANIĆ, D. (1996) Arteriography after ligation of the brachial and femoral artery in the dog. *Veterinary Medicine (Prague)* **14**, 319-322

CEARGE, S., SAITO, I. & FIKAT, M. M. (1995) Retrieval of an embolisation coil from the internal carotid artery using the Amplatz Microsnare retrieval system. *Cardiovascular and Interventional Radiology* **18**, 262-264

CHRISTIE, B. A. (1980) Collateral arterial blood supply to the normal and ischemic canine kidney. *American Journal of Veterinary Research* **41**, 1519-1525

CHUNG, V. P. (1979) Non-operative retrieval of Gianturco coils from abdominal aorta. *American Journal of Roentgenology* **132**, 996-997

CHUNG, V. P., WALLACE, S. & GIANTURCO, C. (1981) Complications of coil embolisation: prevention and management. *American Journal of Roentgenology* **137**, 809-813

EDWARDS, R. D., TAYLOR, A. & ROBERTSON, I. R. (1993) Percutaneous retrieval of a misplaced coil. *Clinical Radiology* **48**, 143-144

FISHER, G. R. & FEESEYER, R. (1978) Evaluation of current techniques for non-surgical removal of intravascular foreign bodies. *American Journal of Radiology* **130**, 541-548

FOX, P. R., SOCS, T. A. & BOND, B. R. (1985) Nonsurgical

removal of a catheter embolus from the heart of a dog. *Journal of the American Veterinary Medical Association* **187**, 275-276

GLAUS, T. M., GAIDELLE, O. & BASS, M. (1999) Closure of a persistent ductus arteriosus of Botallo in two dogs using transarterial coil embolisation. *Schweizer Archiv für Tierheilkunde* **141**, 191-194

HOSKINSON, J. J., WOOTEN, P. & EWANS, R. (1991) Non-surgical removal of a catheter embolus from the heart of a foal. *Journal of the American Veterinary Medical Association* **199**, 233-235

MILLER, M. W. (2000) Interventional cardiology: catheter occlusion of PDA in dogs. In: *Current Veterinary Therapy XII*, Ed J. D Bonagura, W. B. Saunders, Philadelphia, p 742

RAWLINGS, C. A., CALVERT, C. A. & GLAUS, T. M. (1994) Surgical removal of heartworms. *Seminars in Veterinary Medicine and Surgery* **9**, 200-205

SAUNDERS, J. H., SHAPS, F. & PEETERS, D. (1999) Use of a balloon occlusion catheter to facilitate transarterial coil embolisation of a patent ductus arteriosus in two dogs. *Veterinary Record* **145**, 544-546

SHAPS, F. R., MCKENTEE, K. & SAUNDERS, J. H. (1995) Treatment of patent ductus arteriosus by placement of intravascular coils in a pup. *Journal of the American Veterinary Medical Association* **207**, 724-725

STOKROF, A. A., SHEERAN, N. & WOLVERAMP, T. C. (2000) Transcatheter closure of PDA using occluding spring coils. *Journal of Veterinary Internal Medicine* **14**, 452-455

TAJIMA, H., GEMMA, K. & HAYASHI, H. (1994) Successful retrieval of coil after unintentional embolisation of portal vein system: a case report. *Radiation Medicine* **12**, 87-88

TAKEHASHI, N., MATSU, A. & SAKKA, H. (1988) Feline caval syndrome. *Journal of the American Animal Hospital Association* **24**, 645-649

THOMAS, J., SACLAR-SMITH, B. & BLOOMFIELD, D. (1964) Non-surgical retrieval of a broken segment of a steel spring guide from the right atrium and inferior vena cava. *Circulation* **30**, 106-108

TOYOTA, H., FUSE, S., HIRAYAMA, K. & CHBA, S. (2000) Endothelialization of the coils used to occlude a persistent ductus arteriosus. *Japanese Circulation Journal* **64**, 262-264

VAN ISRAËL, N., FRENCH, A. T., WOOTEN, P. R. & WILSON, N. (2001) Hemolysis associated with PDA coil embolization. *Journal of Veterinary Internal Medicine* **15**, 153-156

VUJIC, I., MOORS, L. & McWEY, R. E. (1986) Retrieval of a coil after unintentional embolisation of ileocolic artery. *Radiology* **160**, 563-564

WEBER, J. (1990) A complication with the Gianturco coil and its non-surgical management. *Cardiovascular and Interventional Radiology* **3**, 156-158

WHIGHAM, H. M., ELLISON, G. W. & GERRARD, J. (1998) Aortic foreign body resulting in ischemic neuromyopathy and development of collateral circulation in a cat. *Journal of the American Veterinary Medical Association* **213**, 829-832

YEDLICKA, J. W., CARLSON, J. E. & HUNTER, D. W. (1991) Nitinol gooseneck snare for removal of foreign bodies: experimental study and clinical evaluation. *Radiology* **178**, 691-693